

CASE STUDY

Resolution of Secondary Amenorrhea Following Reduction of Vertebral Subluxations: A Case Report

Lori Goodsell, D.C.¹ & Ian Shtulman, D.C.²

Abstract

Objective: To describe the results of chiropractic care on a female with secondary amenorrhea.

Clinical Features: A 21-year-old female presented to a chiropractic office with a 5 year history of back pain and amenorrhea following sacral trauma. Physical exam revealed indicators of vertebral subluxation including motion and static palpation abnormalities, postural alterations, as well as paraspinal thermography and surface electromyography asymmetries.

Intervention and Outcomes: Vertebral subluxations were found at C1, T1, T11, and L4. Adjustments were delivered using specific, high-velocity, low-amplitude thrusts, using Motion Palpation technique. Twelve weeks into care the patient reported having her first normal menstrual cycle in 5 years. At 16 weeks of care she reported having normal, regular menstrual cycles for the first time in her life.

Conclusions: Chiropractic care may play a beneficial role in reproductive health. More research is warranted to further explore the possible physiological implications of vertebral subluxation.

Key Words: *Amenorrhea, chiropractic, dysafferentation, infertility, subluxation*

Introduction

Secondary amenorrhea is defined as the absence of menses in a female with previous menstrual cycles.¹ Absence of menses must be 3 months or longer in previously normal females, and 9 months or longer in females previously with oligomenorrhea.

Secondary amenorrhea is more common than primary amenorrhea, described as a female failing to reach menarche by age 16.² Approximately 3% of women of child-bearing age are affected, but it is more common in young, nulliparous females, affecting 8.5% of high school girls. Besides psychological issues, chronic amenorrhea can lead to more significant health concerns including osteoporosis and endometrial cancer.¹

Current medical care for secondary amenorrhea starts with ruling out pregnancy, the most common cause. A complete history is important and should review reproductive health, sexual history, family history, current or past medicine, and lifestyle stress.¹ Medical testing includes measuring thyroid stimulating hormone, prolactin, progesterone, estrogen, follicle stimulating hormone, and luteinizing hormone.² Despite extensive testing, 15% of cases are idiopathic.¹

Oral contraceptives, used to regulate the menstrual cycle, are the most common form of treatment. However, insufficient research about form and dose, as well as long-term side effects, makes oral contraceptives a less than ideal solution.^{3,4}

This paper reviews the case of a woman with secondary amenorrhea undergoing chiropractic care. Chiropractic care is

1. Private Practice of Chiropractic, Plymouth, MN, USA

2. Private Practice of Chiropractic, Lake Worth, FL, USA

focused on the location and reduction of vertebral subluxation, which the Association of Chiropractic Colleges defines as “a complex of functional and/or structural and/or pathological articular changes that compromise neural integrity and may influence organ system function and general health.” The amount of research concerning chiropractic care and reproductive health is limited, however anecdotal evidence is available.⁵

Case Report

Patient History

This case report focuses on a 21-year-old female presenting to a chiropractic office for back pain and amenorrhea of 5 years duration. History revealed menarche had been at 7.5 years and her medical doctors diagnosed her with precocious puberty. She was prescribed Lupron injections, a medication commonly used in precocious puberty to induce amenorrhea and delay the onset of puberty, until the age of 9.5 when her medical doctors believed it was appropriate for her to begin menstruation.⁶

She reported irregular cycles for 5 years until the age of 15 when they became infrequent, every 3-4 months until they ceased completely at age 16. The patient stated that she continued to experience menstrual cramps regularly despite the absence of menses. She was placed on oral contraceptives to help regulate her cycle, but reported her menstrual bleeding became extremely heavy and the drugs negatively impacted her emotional state that led to her discontinuing use of the medication. The patient also reported experiencing a fall on a cement floor, injuring her low back, around the same time her menstruation ceased.

Past medical history revealed the patient had undergone medical testing for a fatty mass at her cervicothoracic transitional area. Her medical doctor ordered lab tests to assess thyroid function, which returned as within normal range. No other testing was performed.

Examination

A physical exam was performed to assess the patient for vertebral subluxations. Postural evaluation revealed a cervicothoracic kyphosis. Static and motion palpation of the spine revealed segmental fixation, muscular hypertonicity, and localized tenderness at the levels of C1, T1, T11, and L4.

Thermography and surface electromyography (sEMG) were performed using the Insight Millennium Subluxation Station. Paraspinal infrared thermography assesses autonomic nervous system function by measuring skin temperature differentials.

Skin temperature is regulated via the sympathetic nervous system and can be used as a tool to assess autonomic function. Prior studies show a relationship between vertebral subluxation and autonomic nervous system dysfunction. Thermal asymmetries of 0.5° C are considered significant and an indication of abnormal autonomic regulation.^{6, 7} Initial scans of the patient revealed mild dysautonomia at C6 and T2, moderate dysautonomia at L3 and S1, and severe dysautonomia at C2, L2, L4, L5 (Figure 1).

Paraspinal surface electromyography (EMG) is a measurement of the electrical activity of muscles. Aberrant muscle activity is an acknowledged manifestation of vertebral subluxation, therefore using surface EMG is a reliable outcome assessment for chiropractic care. Symmetry, a comparison of left-right amplitudes at each spinal level, is an important way to assess the scans.⁸ One standard deviation from normal is considered mild asymmetry, two standard deviations are moderate, and three standard deviations are severe. Initial scans revealed mild asymmetry at C5, T1, T4, and L5, moderate asymmetry at T10, and severe asymmetry at T8 (Figure 2).

Intervention & Outcomes

Following a report of findings and informed consent, chiropractic care began one week later at a frequency of three times per week. Vertebral subluxations were located and adjustments were performed using Motion Palpation technique, an approach that considers a vertebral subluxation to be an alteration in normal intervertebral motion.⁹ High-velocity, low-amplitude thrusts were delivered manually to subluxated segments based on static and motion palpation, leg length deficiencies, and/or visual observation.

Approximately 6 weeks into care an Activator Adjusting Instrument was used to adjust C1. The Activator Adjusting Instrument is a hand-held instrument that provides a high-velocity, low-amplitude, mechanical force in place of a manual adjustment.

Four weeks following the start of care, at a progress exam, the patient reported experiencing better posture, more energy, and improvement in overall health. Thermal scans showed only mild dysautonomia at T2 and T3, a significant improvement in skin temperature differential and autonomic function (Figure 3). Surface EMG scans showed mild asymmetry at C3, T2, T8, L1, and L3 (Figure 4). The thermal and sEMG scans show objective improvement in indicators of vertebral subluxation.

At a second progress exam, 8 weeks into care, she reported performing excessive physical activity while helping her friend move, which may have contributed to increased asymmetry in both thermal and sEMG scans (Figures 5 and 6).

Four weeks later, at a third progress exam and 12 weeks into care, her scans significantly improved from the previous exacerbation. (Figures 7 and 8). Additionally, the patient reported the start of her menstrual cycle for the first time in 5 years. She reported losing weight and having regular menstrual cycles at 16 weeks into care, which has continued to be normal since. The patient continues to undergo chiropractic care for the location and reduction of vertebral subluxation.

Discussion

Secondary amenorrhea is a common condition affecting 3% of females of child-bearing age and 8.5% of younger, nulliparous females. The most common cause is pregnancy and 15% of cases are considered to be idiopathic. Recommendations for a chiropractor include performing a thorough history, physical exam, and rule out pathology including abnormal hormone

levels. If no clear pathology is evident, location and reduction of vertebral subluxations is an option.^{1, 10} Some inorganic causes of secondary amenorrhea can include eating disorders, excessive exercise, medication side-effects, and lifestyle stress.³ The chiropractor should keep in mind lifestyle-related causes in addition to subluxation reduction.

Evidence of vertebral subluxation affecting reproductive health exists mostly in case study form. Curtis and Young reported two cases of women with secondary amenorrhea. In Case A, an 18-year-old female presented with a 4 year history of amenorrhea. She experienced adverse reactions to oral contraceptives and decided not to use them anymore. During a history she reported having two traumas to her spine as a child. After 8 adjustments in 14 weeks of care she started a normal menstrual cycle. Case B is a 17-year-old female with a one year history of amenorrhea. A physical exam revealed torsion of the pelvic girdle. She returned to a normal menstrual cycle in two months of care.¹

Gauthier and Mullin reported a case of a 25-year-old female with primary amenorrhea. At age 18 she was placed on oral contraceptives, which removed symptoms, but they returned 4 years later when she stopped taking them. She started her menstrual cycle following 4 visits with adjustments to occiput and sacrum. It was unclear if adjustments were the only method that helped because the patient also used a topical progesterone cream recommended by the chiropractor.³

Sims and Lee discussed a 23-year-old female presenting with a chief complaint of infertility. She reported a history of amenorrhea followed by oral contraceptive therapy at age 17. Using Diversified, Toggle, and Webster chiropractic techniques, the patient returned to menstruation in 3.5 months and reported being pregnant at 4.5 months into care.⁷

Adams reported a case of a 22-year-old female with Type 1 Diabetes and primary amenorrhea. She received 3-4 adjustments per month for the first 4 months, when she reported experiencing menarche. Eight adjustments were delivered over the next 15 months to sacrum and other subluxations. She reported becoming pregnant and delivering a baby following chiropractic care.¹¹

A direct relationship between the nervous system and reproductive organs has been established. These organs are supplied by ovarian and uterovaginal plexuses from the superior and inferior hypogastric plexuses.¹⁰ Bula referenced McNabb who suggested lower thoracic subluxations could irritate the sympathetic innervations to the fallopian tubes and uterus. Irritation to the nerves could cause excess vasomotor tone resulting in physiological dysfunction without causing pathology. Bula also referenced Simon who hypothesized that altered regulation of pituitary hormones or abnormal nervous system influences could be responsible for infertility.¹²

Genders et al. observed a strong correlation between dysmenorrhea and sacroiliac joint dysfunction. Sacroiliac joint dysfunction is considered to be a hypomobility due to altered structural and/or articular relationships between ilium and sacrum. They hypothesized that a chiropractic adjustment can alter smooth muscle contraction of the uterus by reducing irritation to the parasympathetic supply via S2-S4.¹³

Kokjohn et al. performed a study measuring the effect of spinal manipulative therapy on menstrual distress and dysmenorrhea. Subjects were divided into either a sham adjustment group or a spinal manipulative therapy (SMT) group. The SMT was performed by placing the subject in a side-lying position with the bottom leg straightened and top leg bent while applying a high-velocity, low-amplitude thrust to a vertebra between T10 and S1.

The sham adjustment was performed by placing the subject in a side-lying position with both legs bent and a high-velocity, low-amplitude thrust given to the midline of sacrum. It was considered a sham adjustment because it was designed to not create enough tension to cause movement of a bone, however it must be questioned whether delivering a high-velocity, low-amplitude thrust to the area would not cause some physiological reaction.

Both the sham and SMT group experienced reduction in the level of plasma KDPGF_{2a}, a metabolite of endometrial prostaglandin suspected of being a principal cause of dysmenorrhea. The SMT group also reported decreases of pain and menstrual distress twice as great as the sham group. This is evidence that spinal adjustments could create physiological changes to the tissue of reproductive organs.⁴

Further evidence of reproductive health benefits is through multiple case studies of previously infertile females. Kaminski reported a case of a 31-year-old female diagnosed with a "lazy system" and infertility by her medical doctor. Chiropractic exam revealed thermal asymmetry at the levels of sympathetic input to reproductive organs. Two months into chiropractic care the patient reported a normal menstrual cycle. Nine months into care she reported being 9 weeks pregnant.⁶

Phillips reported a case of a 37-year-old female with a history of endometriosis, 4 failed in-vitro fertilization procedures, and a diagnosis of infertility. Four months into chiropractic care she reported returned follicular activity for the first time, followed by a successful in-vitro fertilization.¹⁰

Alcantara, Stern, and Oman discussed three cases of infertile females. The first case conceived after 4 months of initiating care following a 4-year history of infertility. The second patient reported two years of unsuccessful medical reproductive assistance. She conceived following three months of chiropractic care. The third patient became pregnant 12 days after starting chiropractic care following 7 months of unsuccessful attempts.¹⁴

Senzon reported the case of a 34-year-old female undergoing in-vitro fertilization. Previous follicle growth was only 4 small follicles and considered a "poor responder." After Network Spinal Analysis, a light-touch chiropractic technique, follicle growth increased to 10. Senzon hypothesized that Network Spinal Analysis may contribute to a "sympathetic quieting" that allows for better autonomic regulation.¹⁵

A possible mechanism could be explained using the dysafferentation model of vertebral subluxation described by Kent. Spinal dysfunction in the form of abnormal intervertebral motion alters the balance of mechanoreceptive

and nociceptive input to the central nervous system. This aberrant afferent information leads to dysponesis, a term used to describe the resultant errors in neurological functioning following altered input. When afferent input is compromised, the quality and quantity of efferent signals will be altered. Chiropractic adjustments could improve neurological functioning by correcting afferent input.¹⁶ This provides a model as to how chiropractic care can have effects far from the adjusted segment.

Dysafferentation is an imbalance in afferent input due to increased nociceptive and decreased mechanoreceptive levels.¹⁷ Nociceptors usually have thresholds higher than light touch and normal movement can depolarize. Injured tissues, such as those involved in vertebral subluxation, release chemical mediators (Prostaglandin E-2, Leukotriene B-4, Bradykinin, Histamine, 5-Hydroxytryptamine) that can lower this threshold, making it easier for normal movements to depolarize the nociceptors.¹⁷

Nociceptive threshold can be lowered further with the release of prostaglandin by tissues during a sympathetic discharge, which Korr previously associated with subluxations.^{16, 17} A higher rate of nociceptive input to the central nervous system, associated with aberrant spinal motion from subluxations, can cause asymptomatic neuroendocrine responses, which may play a role in multiple disease processes.¹⁷

Nociception also increases cortisol levels. In excess amounts, cortisol can drain protein from the body and cause a variety of tissue-specific changes such as decreased rapid-eye-movement sleep, decreased cell-mediated immunity, decreased osteoblast proliferation, and decreased collagen synthesis. With the resultant hypercortisolemia, pain may not be the main symptomatic outcome of nociceptive input.¹⁷

Mechanoreceptors are also affected by aberrant spinal motion. Found in skin, muscles, joint structures, and intervertebral discs, mechanoreceptors provide important sensory input to the central nervous system. Decreased joint movement decreases mechanoreceptor activation, increasing segmental sympathetic hyperactivity. As previously mentioned, increased sympathetic activity will act to further lower the threshold of nociceptors and increase cortisol levels.¹⁷

Muscle spindles, an important type of mechanoreceptor, are found in greatest concentration in muscles of fine movement and posture, especially the neck. The rectus femoris muscle has 50 muscle spindles per gram of tissue, compared to 150-200/gram in the suboccipital muscles and 200-500/gram in the intertransverse muscles in the cervical spine. Golgi tendon organs, another form of mechanoreceptors, are also found in high concentrations in the neck. The potential for mechanoreceptive input to the central nervous system is significantly higher in the cervical spine than most areas of the body.

Joint complex dysfunction or vertebral subluxations, have been associated with degeneration of mechanoreception-rich tissues. A vertebral subluxation, or aberrant spinal motion, would therefore greatly reduce the mechanoreceptive afferent input to the central nervous system.¹⁷ It is hypothesized that this dysafferentation, associated with vertebral subluxation,

could explain why “seemingly bizarre symptoms respond to chiropractic care.”¹⁷

The case presented in this paper could be explained through the dysafferentation model of vertebral subluxation. The patient is a 21-year-old female presenting with secondary amenorrhea following a sacral trauma. This injury, or a previous injury, could have resulted in the initial vertebral subluxations and lowered nociceptive threshold.

The physical exam revealed areas of intersegmental hypomobility, and asymmetrical paraspinal thermal and sEMG readings. The increased thermal reading represents the abnormal autonomic nervous system regulation created by the subluxations and altered nociceptive and mechanoreceptive input.

The sEMG reading represent areas of localized increased electrical activity, an accepted sign of vertebral subluxation.⁸ It is important to note that sEMG readings showed severe asymmetry at the regions associated with sympathetic supply to the reproductive organs.

Following chiropractic adjustments, the scans (Figures 3 and 4) show a normalization of autonomic function and more symmetric electrical activity to the muscles compared to initial scans (Figures 1 and 2), indicating a reduction in these components of vertebral subluxations. Following 12 weeks of chiropractic care to reduce vertebral subluxations, the patient experienced a normal menstrual cycle. As Kent noted, chiropractic adjustments may correct abnormal afferent input and improve neurological functioning throughout the body.¹⁶

Conclusion

This case, as well as the reviewed literature, shows that chiropractic may play a beneficial role in reproductive health. Thermography and sEMG scans were beneficial to the determination that this patient had vertebral subluxations contributing to abnormal nervous system regulation. Of more interest is the reduction of vertebral subluxations, the effect on autonomic nervous system function, and subsequent resolution of secondary amenorrhea. Conclusions based on this one case are limited, however it should encourage more research into chiropractic care and reproductive health.

The chiropractic profession needs to further develop and explore the possible physiological implications of vertebral subluxations. Published research for non-musculoskeletal complaints in chiropractic care is limited to mostly case studies. While research of neck and back pain is common in chiropractic, it is the authors' belief that future resources need to be devoted to the further understanding of locating subluxations, reducing subluxations, and the physiological benefits of that reduction.

References

1. Courtis G, Young M. Chiropractic management of idiopathic secondary amenorrhea: a review of two cases. *Br J Chiropr.* 1998 Apr; 2(1): 12-14.

2. Master-Hunter T, Heiman DL. Amenorrhea: Evaluation and Treatment. *Am Fam Phys.* 2006 Apr 15; 73(8): 1374-1382.
3. Gauthier E, Mullin L. The Effects of Gonstead Chiropractic Care on a Patient with Primary Amenorrhea: A Case Report and Review of Related Literature. *J Pediatr Matern & Fam Health.* 2010 Jul 19: 116-121.
4. Kokjohn K, Schmid DM, Triano JJ, Brennan PC. The Effect of Spinal Manipulation on Pain and Prostaglandin Levels in Women with Primary Dysmenorrhea. *J Manipulative Physiol Ther.* 1992 Jun; 15(5): 279-285.
5. Anderson-Peacock E. Reduction of Vertebral Subluxation using Torque Release Technique with Changes in Fertility: Two Case Reports. *J Vert Sublux Res.* 2003 Jul 19: 1-6.
6. Kaminski TM. Female Infertility and Chiropractic Wellness Care: A Case Study on the Autonomic Nervous System Response while Under Subluxation Based Chiropractic Care and Subsequent Fertility. *J Vert Sublux Res;* 2003 Nov 2: 1-10.
7. Sims LE, Lee J. Resolution of Infertility in a Female Undergoing Subluxation Based Chiropractic Care: Case Report & Review of Literature. *J Vert Sublux Res.* 2008 Aug 6: 1-6.
8. Kent C. Surface Electromyography in the Assessment of Changes in Paraspinal Muscle Activity Associated with Vertebral Subluxation: A Review. *J Vert Sublux Res.* 1997; 3(1): 1-8.
9. King SW, Stephenson G. The Motion Palpation Institute: 25 Years and Counting [Internet]. *Dynamic Chiropractic.* 2006 Feb 27; 24(5) [cited 2010 Dec 1]. Available from: <http://www.dynamicchiropractic.com/mpacms/dc/article.php?id=51092>
10. Phillips G. Changes in Ovarian Function After Chiropractic Adjustments in Woman Diagnosed with Infertility. *J Clin Chiropr Ped.* 2006; 7(1): 458-460.
11. Adams J. Chiropractic and Nutritional Management and its Effect on the Fertility of a Diabetic Amenorrheal Patient: A Case Report. *J Vert Sublux Res.* 2003 Oct 12; 1-2.
12. Bula SM. Infertility and chiropractic: A review of the literature. *J Clin Chiropr Ped.* 2008 Mar; 9(1): 567-571.
13. Genders G, Hopkins SS, Lean EK, Bull PW. Dysmenorrhea and Pelvic Dysfunction: A Possible Clinical Relationship. *Chiropr J Aust.* 2003 Mar; 33(1): 23-29.
14. Alcantara J, Stern G, Oman RE. Female Infertility, Subluxation & Chiropractic Care: A Case Series and Selective Review of the Literature. *J Pediatr Matern & Fam Health.* 2009 Jun 8: 1-10.
15. Senzon SA. Successful In Vitro Fertilization in a Poor Responder While Under Network Spinal Analysis Care: A Case Report. *J Vert Sublux Res.* 2003 Sep 14: 1-6.
16. Kent C. Models of Vertebral Subluxation: A Review. *J Vert Sublux Res.* 1996 Aug; 1(1): 1-7.
17. Seaman DR, Winterstein JF. Dysafferentation: a Novel Term to Describe the Neuropathophysiological Effects of Joint Complex Dysfunction: A Look at Likely Mechanisms of Symptom Generation. *J Manipulative Physiol Ther.* 1998 May; 21(4): 267-279.

Instrumentation

A series of thermal and surface electromyography scans were performed throughout the course of care. Four thermal scans and four SEMG scans were performed.

Instrumentation revealed what appear to be consistent cervical, thoracic, and lumbar spine hypertonicity and dysautonomia during the care intervals reported.

Follow-up thermal scanning, at 4 weeks, revealed a decrease in the dysautonomia in the cervical region from the initial scan. This was followed by an exacerbation, thus shown on follow up scan at 8 weeks. By 12 weeks, there was again a decrease in the dysautonomia.

Follow-up surface electromyography scanning, at 4 weeks, revealed a decrease in hypertonicity throughout the spine, with the largest reduction at T8. As previously noted, there was an exacerbation at 8 weeks, therefore increasing hypertonicity overall, then decreasing on follow up scanning at 12 week visit.

Figure 1 – Initial Thermal Scan

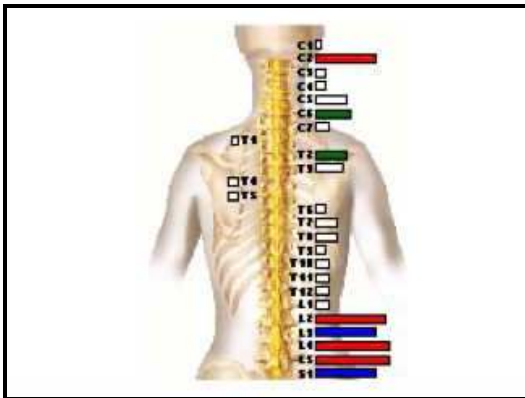


Figure 2 – Initial Surface Electromyography Scan

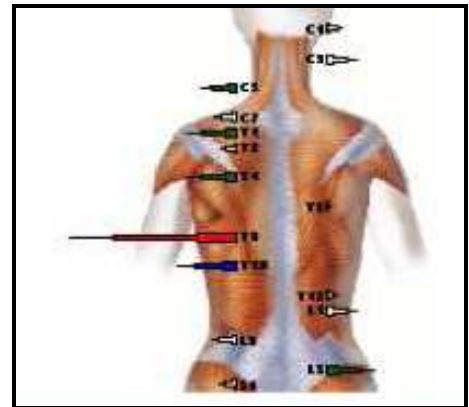


Figure 3 – Thermal Scan – 4 Weeks Later

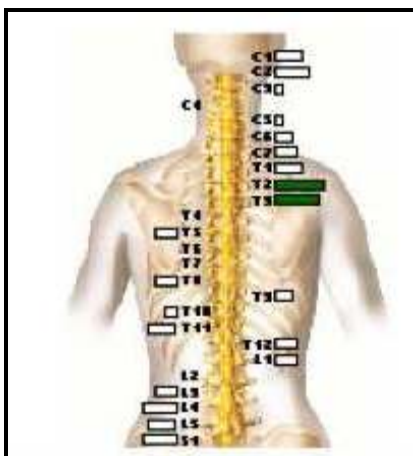
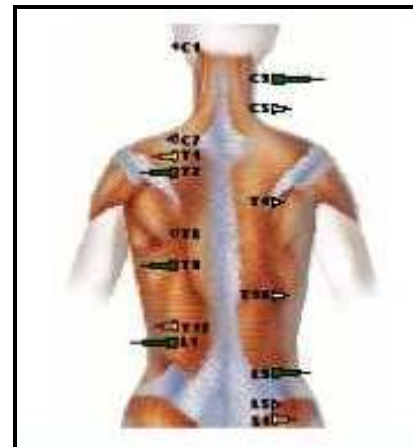
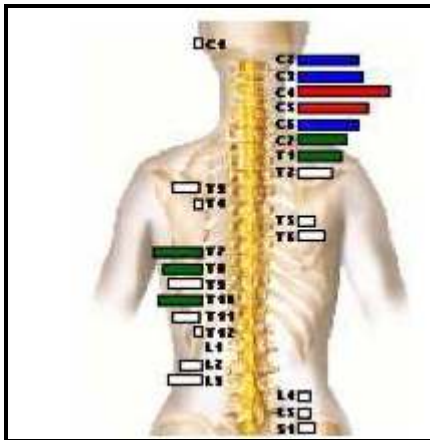


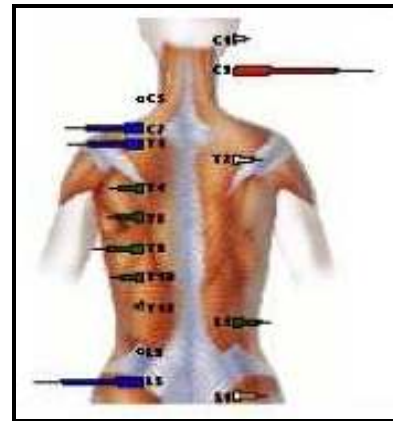
Figure 4 – Surface Electromyography Scan – 4 Weeks Later



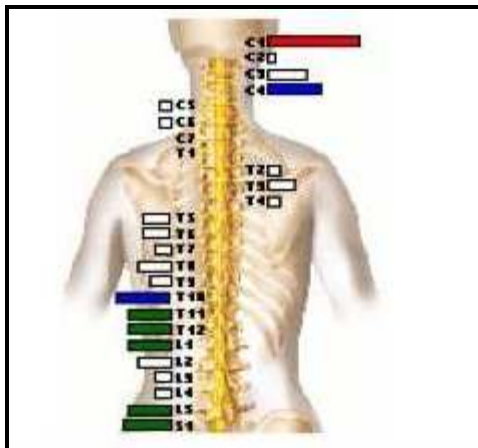
**Figure 5 – Thermal Scan –
8 Weeks Later**



**Figure 6 – Electromyography Scan –
8 Weeks Later**



**Figure 7 – Thermal Scan –
12 Weeks Later**



**Figure 8 – Electromyography Scan –
12 Weeks Later**

